



## Alveolar bone defect regeneration after bilateral periapical cyst removal with and without use of platelet rich fibrin – A case report

Zarastanje koštanog defekta nastalog enukleacijom bilateralnih periapikalnih cista sa i bez upotrebe fibrina obogaćenog trombocitima

Nemanja Vuković\*, Marjan Marjanović\*, Bojan Jovičić†‡, Ema Aleksić§,  
Katarina Kalevski||, Nenad Borotić||, Djordje Pejanović\*, Marko Andjelković\*\*

University of Business Academy in Novi Sad, Faculty of Dentistry, \*Clinic for Oral Surgery and Implantology, †Clinic for Mouth Diseases, §Clinic for Orthodontics, ||Clinic for Child and Preventive Stomatology, ¶Clinic for Prosthodontics, Pančevo, Serbia; Military Medical Academy, ‡Clinic of Dentistry, Belgrade, Serbia; University of Belgrade, Faculty of Dental Medicine, \*\*Department of Prosthodontics, Belgrade, Serbia

### Abstract

**Introduction.** Periapical inflammatory lesions are local bone responses around the apex of a tooth that occur after necrosis of the pulp tissue. The ultimate goal of reconstructive surgical techniques in the treatment of the intra-bone defects is a regeneration of lost bone tissue. The aim of this report was to evaluate clinical and radiographic outcome following the removal of two big, periapical lesions, approximately of the same size, located around maxillary lateral incisors, in the same person at the same time, using two different regenerative approaches. **Case report.** A healthy, 21-year-old female presented with two large periapical lesions around both upper lateral incisors, and a surgical treatment was indicated. One residual defect (tooth #12) was filled with the mixture of bovine-derived hydroxyapatite xenograft and platelet rich fibrin (PRF) gel and covered with PRF membrane, while the other (tooth #22) was filled with bovine-derived hydroxyapatite xenograft only and covered with a resorbable collagen membrane. Clinical and radiographic examinations were performed seven months after the surgery. All clinical and radiographic parameters were significantly improved after the treatment on both sites; however, a newly formed bone around the tooth 12 showed a higher bone density. **Conclusion.** The use of PRF significantly speeded up filling of the defect compared to bovine-derived hydroxyapatite xenograft.

### Key words:

oral surgical procedures; platelet rich plasma; bone regeneration.

### Apstrakt

**Uvod.** Inflammatorne periapikalne lezije su posledica širenja infekcije iz kanala korena zuba. Cilj moderne periapikalne hirurgije je uklanjanje lezija u celosti, kako bi se omogućila potpuna restitucija periapikalnog, sa težnjom da se povrti izgubljeno koštano tkivo. Cilj ovog prikaza bolesnika bio je da se klinički i radiografski proceni rezultat zarastanja koštanog defekta nakon uklanjanja dve velike periapikalne ciste kod iste osobe u isto vreme, koristeći dva različita regenerativna pristupa. **Prikaz bolesnika.** Kod zdrave, dvadesetjednogodišnje bolesnice dijagnostikovane su dve periapikalne ciste gornjeg levog i desnog lateralnog sekutića i indicirano njihovo hirurško uklanjanje. Jedan koštani defekt je popunjen mešavinom serumskog eksudata dobijenog kompresijom plazme obogaćene fibrinom (PRF) ugruška i govedjeg koštanog ksenografta, a zatim prekriven membranom od PRF. Drugi defekt popunjen je korišćenjem samo hidratisanog govedjeg koštanog ksenografta i prekriven resorptivnom kolagenom membranom. Kliničko i radiografsko ispitivanje izvršeno je sedam meseci posle hirurškog tretmana. Svi klinički i radiografski parametri bili su značajno poboljšani posle tretmana na oba mesta. Međutim, novoformirana kost oko zuba br. 12 imala je veću koštanu gustinu. **Zaključak.** PRF je značajno ubrzao zarastanje koštanog defekta.

### Ključne reči:

hirurgija, oralna, procedure; plazma bogata trombocitima; kost, regeneracija.

## Introduction

Periapical inflammatory lesions are local bone responses around the apex of a tooth that occur after necrosis of the pulp tissue caused by dental caries, mechanical or thermal trauma and chemical agents. Modern periapical surgery aims to remove periapical lesions to achieve complete wound healing and aid regeneration of bone and periodontal tissue. Since natural healing takes a relatively long period of time for the bone to fill the residual cavity<sup>1</sup>, regenerative approaches that help restore lost tissue and speed up regeneration have been introduced<sup>2,3</sup>. Regeneration is the process of reproduction or reconstitution of a lost or injured part of the body in such a way that the architecture and function of the lost or injured tissues are completely restored, and it is a natural process of wound healing. The ultimate goal of reconstructive surgical techniques in the treatment of intra-bone defects is a regeneration of lost bone tissue.

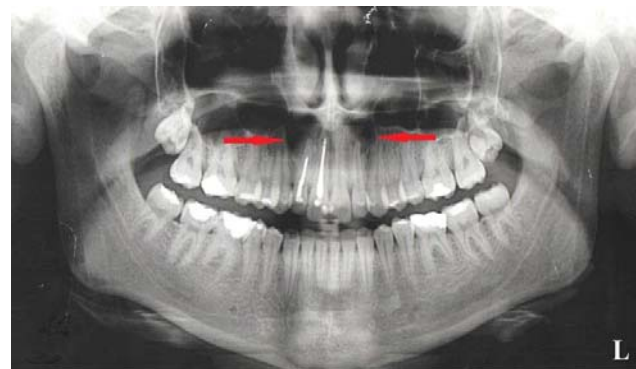
Many regenerative techniques, utilizing bone grafts and barrier membranes, were introduced to help the optimal healing of the residual defects after the removal of intra-bone lesions, especially large cysts<sup>4-6</sup>. Lately, the use of platelet rich fibrin (PRF) showed very promising results in regenerative surgical procedures<sup>7</sup>, although autologous platelet concentrates and their advantages are already very well-known<sup>8</sup>. The PRF technique was developed in 2001 by Joseph Choukroun and associates with the idea to combine characteristics of both platelets and growth factors into a fibrin clot in order to accelerate healing and remodeling of bone and soft tissue<sup>9</sup>.

So far, there has been no consensus on whether or not alveolar bone defects left after large periapical cysts removal should be filled with bone grafts or other healing inducing derivate<sup>10</sup>, but the positive effects these techniques have on alveolar bone formation are undisputed<sup>11</sup>. The aim of this report was to show clinical and radiographic outcome following the removal of two big periapical lesions, approximately of the same size, located around maxillary lateral incisors, in the same person at the same time, using different regenerative approaches.

## Case report

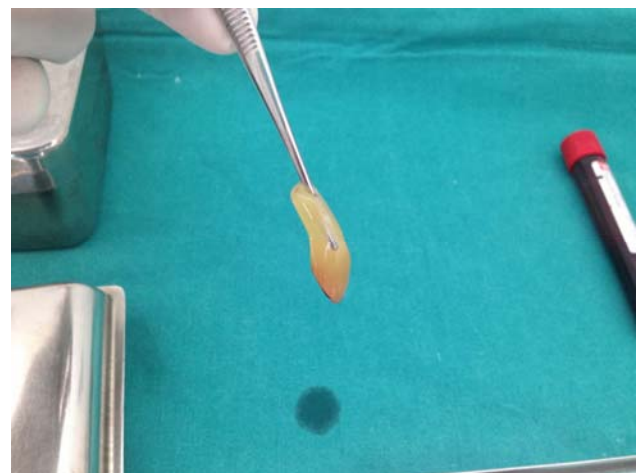
A healthy, 21-year-old female patient complaining of the pain in the upper left anterior region presented to the Department of Conservative Dentistry and Endodontics, Faculty of Dentistry in Pančevo. During the intraoral examination, a slight discoloration of upper left lateral incisor was observed; tooth was mobile and sensitive to vertical percussion, with non-exudative swelling in the apical region. The patient was provided with the first aid dental treatment and sent to the Department of Radiology. The panoramic radiograph revealed the presence of periapical intrabony defects around apices of teeth #12 (approximately 13 mm in diameter) and #22 (11 mm in diameter) and inadequate endodontic treatment of the tooth #12 (Figure 1).

Root canal treatment of teeth #12 and #22 was performed just before surgery. The PRF was prepared in accordance with the standard protocol. Just prior to surgery, 30 mL



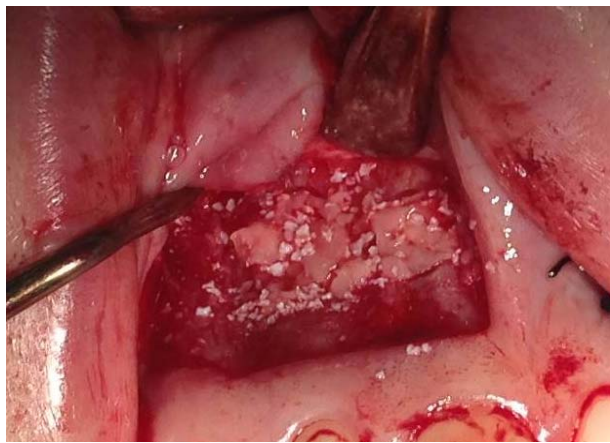**Fig. 1 – The panoramic radiograph before the treatment.**

intravenous blood was collected in a 10-mL sterile tube and immediately centrifuged in centrifugation machine (A-PRF 12, APRF, Nice, France) at 3,000 revolutions per minute for 10 minutes. This protocol of blood centrifugation allows the forming of a 3D fibrin structured clot in the middle of the tube, just between the red corpuscles at the bottom and acellular plasma (platelet-poor plasma) at the top. PRF was easily separated from red corpuscles base (retaining a small red blood cell layer) using sterile tweezers (Figure 2) and scissors just after the removal of the tube and then transferred to a sterile dish.

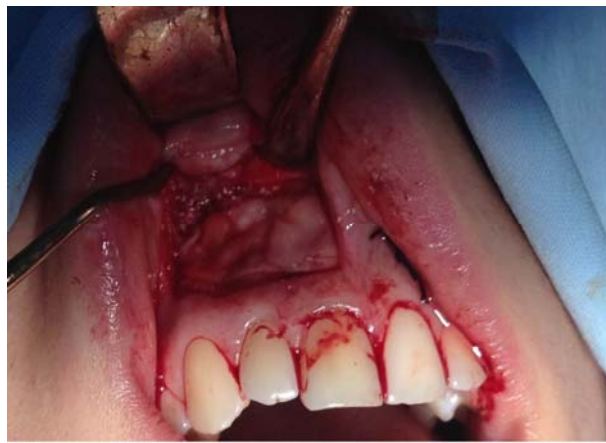

**Fig. 2 – The platelet rich fibrin (PRF) clot.**

After administration of local anesthetic, buccal angular incisions were made and full thickness mucoperiosteal flap was elevated. Labial cortical plate around the apex of the tooth #12 was removed, revealing the periapical intrabony defect in evident relation to the tooth. The cystic lining was enucleated and sent for a biopsy which identified the lesions as radicular cysts. Using tapered fissure bur, tooth root was resected and mineral trioxide aggregate (MTA) (ProRoot MTA; Dentsply, Tulsa, OK, USA) was used as the root end filling material. Bovine-derived hydroxyapatite xenograft (Bio-Oss<sup>®</sup>, GeistlichPharma AG, Switzerland) was sprinkled over the PRF gel and the whole mixture was placed into the defect (Figure 3). PRF membrane was prepared with compresses and placed in two layers over the edge of the defect (Figure 4). The mucoperiosteal flap was repositioned using 3-0 non-absorbable black silk surgical simple interrupted sutures. The same surgical technique was used for the removal



**Fig. 3 – BioOss mixed with platelet rich fibrin (PRF) gel and placed into the defect.**

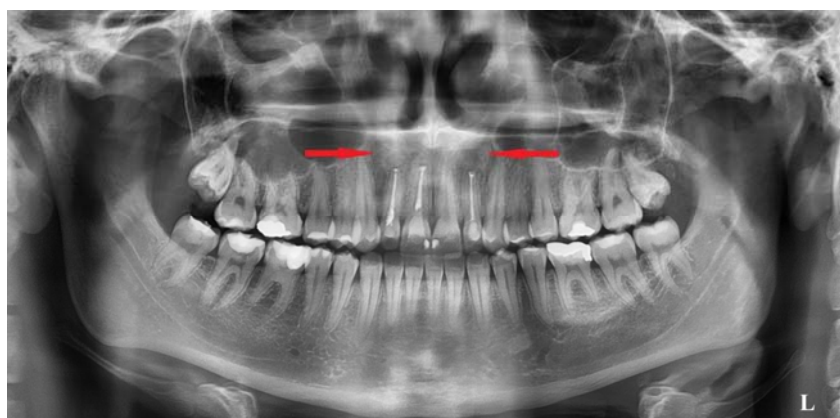

**Fig. 4 – Platelet rich fibrin (PRF) membrane placed over the defect previously filled with the mixture of BioOss and PRF gel (upper right lateral incisor).**

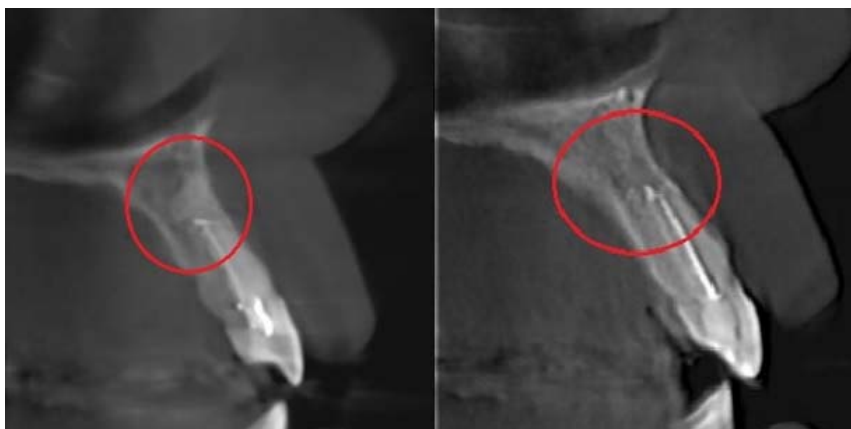
of the tooth #22 periapical lesion, but this time bovine-derived hydroxyapatite xenograft mixed with a physiological solution was placed into bone defect and resorbable collagen membrane (Bio-Gide® COLLAGEN – GeistlichPharma AG, Switzerland) was placed to cover the edge of the defect.

Clinical and radiographic examinations were performed seven months after the surgery. The following param-

eters were evaluated: bone density, alveolar ridge width at the place of residual defect and mobility of the teeth. All clinical and radiographic parameters were significantly improved after the treatment on both sites; however, a newly formed bone around the tooth 12 showed a higher bone density (Figures 5–8). No mobility of teeth was observed at both sites.



**Fig. 5 – The panoramic radiograph after the treatment.**



**Fig. 6 – Region of the former defects filled up with newly formed bone above the root of the tooth #12 (left) and the tooth #22 (right) (Ez3D plus software, Vatech Global, Hwaseong-si, Gyeongii-do, Korea).**

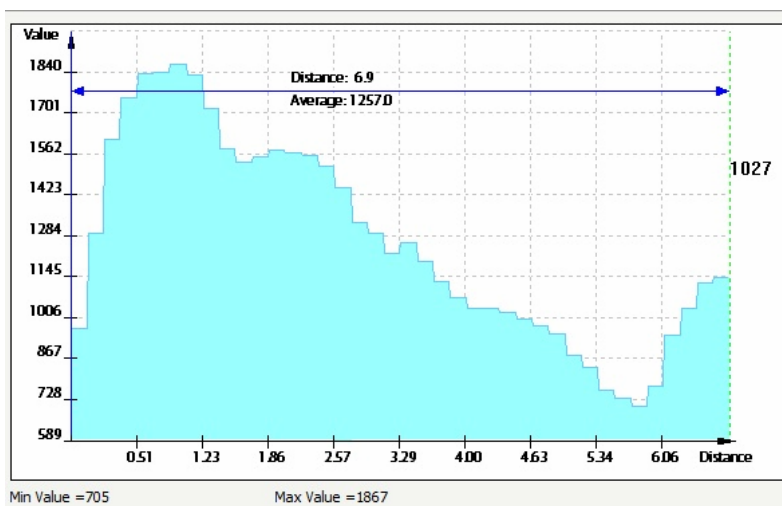


Fig. 7 – Bone density measured in Hounsfield units and alveolar ridge width 3 mm above resected root of the tooth #12 (measured in Ez3D plus software, Vatech Global, Hwaseong-si, Gyeonggi-do, Korea).

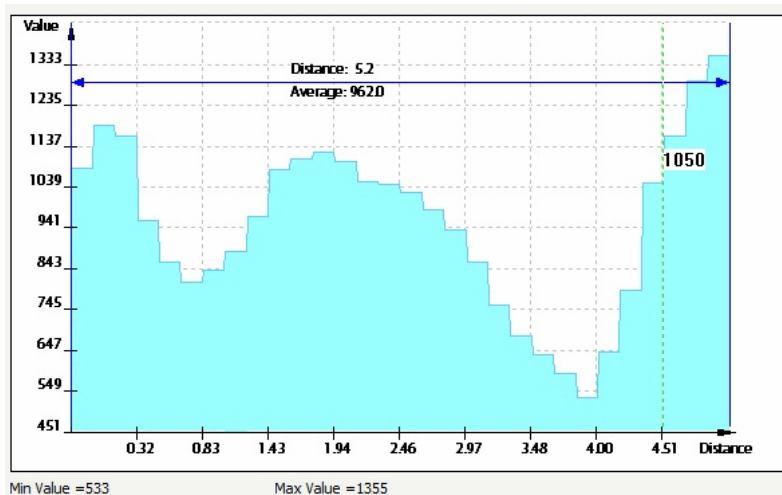


Fig. 8 – Bone density measured in Hounsfield units and alveolar ridge width 3 mm above resected root of the tooth #22 (measured in Ez3D plus software, Vatech Global, Hwaseong-si, Gyeonggi-do, Korea).

## Discussion

After periapical surgery, large bone defects may be created, which sometimes cannot be adequately filled on their own, so the use of suitable graft material is required. PRF is a matrix of autologous fibrin which contains a lot of platelets and intrinsic cytokines within the fibrin mesh, allowing their gradual release over time (7–11 days), correlating with the resorption of fibrin network<sup>9</sup>. The use of PRF grafting offers several advantages: PRF clot and membrane play mechanical role by protecting and linking the grafted biomaterials with themselves and with bone tissue, fibrin network accelerates cellular migration (endothelial cells) necessary for the neo-angiogenesis, platelet cytokines (platelet-derived growth factor – PDGF, transforming growth factor alpha – TGF- $\alpha$ , insulin like growth factor – IGF-1) are released, helping the process of healing, and leukocytes and cytokines in the fibrin network play a significant role in the regulation of inflammatory and infectious processes during wound healing<sup>12, 13</sup>.

PRF is a derivative of patient's own blood, and as such does not trigger an immune response and minimize chances of infectious disease transmission<sup>14</sup>. Preparation of PRF is easy and fast and is done in the dental office immediately before the intervention, which simplifies the procedure and saves the patient of blood harvesting in the hospital<sup>14</sup>.

In this case report, we analyzed the clinical efficacy of PRF autologous graft comparing it with heterologous graft in the treatment of intrabony defects. It was shown that the use of PRF speeds up the filling of the defect compared to bovine-derived hydroxyapatite xenograft.

## Conclusion

This case report indicates that the use of PRF should be considered as a promising solution for a successful augmentation of large bone defects in everyday dental surgical practice.

## R E F E R E N C E S

1. *Chiapasco M, Rossi A, Motta JJ, Crescentini M.* Spontaneous bone regeneration after enucleation of large mandibular cysts: A radiographic computed analysis of 27 consecutive cases. *J Oral Maxillofac Surg* 2000; 58(9): 942–8.
2. *Dablin C, Gottlow J, Linde A, Nyman S.* Healing of maxillary and mandibular bone defects using a membrane technique. An experimental study in monkeys. *Scand J Plast Reconstr Surg Hand Surg* 1990; 24(1): 13–9.
3. *Santamaría J, García AM, Vicente JC, Landa S, López-Arranz JS.* Bone regeneration after radicular cyst removal with and without guided bone regeneration. *Int J Oral Maxillofac Surg* 1998; 27(2): 118–20.
4. *Chen CC, Wang HL, Smith F, Glickman GN, Shyr Y, O'Neal RB.* Evaluation of a collagen membrane with and without bone grafts in treating periodontal intrabony defects. *J Periodontol* 1995; 66(10): 838–47.
5. *Agarwal A, Gupta ND.* Combination of bone allograft, barrier membrane and doxycycline in the treatment of infrabony periodontal defects: A comparative trial. *Saudi Dent J* 2015; 27(3): 155–60.
6. *Bashutski JD, Wang H.* Periodontal and endodontic regeneration. *J Endod* 2009; 35(3): 321–8.
7. *Del Corso M, Toffler M, Doban Ehbrenfest DM.* Use of an autologous leukocyte and platelet-rich fibrin (L-PRF) membrane in post-avulsion sites: an overview of Choukroun's PRF. *J Implant Adv Clin Dent* 2010; 1: 27–35.
8. *Lažić Z, Bubalo M, Petković-Čurčin A, Duka M, Mibajlović B.* Therapeutic use of platelet-rich plasma in oral surgery. *Vojnosanit Pregl* 2009; 66(10): 821–5.
9. *Choukroun J, Adda F, Schoeffler C, Vervelle A.* Une opportunité en paro-implantologie: Le PRF. *Implantodontie* 2001; 42: 55–62. (French)
10. *Eitl T, Gosau M, Sader R, Reichert TE.* Jaw cysts - filling or no filling after enucleation? A review. *J Craniomaxillofac Surg* 2012; 40(6): 485–93.
11. *Oliveira MR, Gabrielli MA, Gabrielli MF, Mariano RC, Pereira Filho VA.* Do platelet concentrates promote bone regeneration? Literature review. *Musculoskelet Regen* 2015; 2: e895.
12. *Nair PR, Pajarola G, Schroeder HE.* Types and incidence of human periapical lesions obtained with extracted teeth. *Oral Surg Oral Med Oral Pathol Oral Radiol Endod* 1996; 81(1): 93–102.
13. *Simonpieri A, Del Corso M, Sammartino G, Doban Ehbrenfest DM.* The relevance of Choukroun's platelet-rich fibrin and metronidazole during complex maxillary rehabilitations using bone allograft. Part I: a new grafting protocol. *Implant Dent* 2009; 18(2): 102–11.
14. *Paramita M, Nag D, Bhunia S.* Treatment of periapical lesion with latelet rich fibrin. *Indian Med Gazette* 2013: 28–33.

Received on December 21, 2015.

Revised on March 25, 2016.

Accepted on April 11, 2016.

Online First July, 2016.